



Effect of Hydroalcoholic Extract of *Teucrium polium* on the Process of Wound Healing in Diabetic Rats

Mohsin Ahmed Salih¹, Asmaa Najm Abdullah², Sadat A. Aziz^{3*}

¹ Department of Histopathology, College of Veterinary Medicine, University of Sulaimani, Kurdistan Region, Iraq

² Department of Pathology, College of Medicine, University of Sulaimani, Kurdistan Region, Iraq

³ Department of Basic Sciences, College of Veterinary Medicine, University of Sulaimani, Kurdistan Region, Iraq

Received 04 January 2020; revised 04 February 2020;
accepted 05 February 2020; available online 23 February 2020

[doi:10.24271/psr.09](https://doi.org/10.24271/psr.09)

ABSTRACT

Wound healing is physiological process, passing through three main overlapping phases, including inflammatory, proliferative, and remodeling phase to repair the damaged tissue. Some vital process in wound healing, including inflammatory cell infiltration, angiogenesis and collagen tissue formation, seems to be disrupted in diabetes, which is a metabolic disorder. The aims of this study were to investigate the effect of different concentrations of hydroalcoholic extract of *Teucrium polium*, which is a medicinal plant, on the process of wound healing in diabetic rats. Diabetes were induced in twenty adult Albino-rats using a single intraperitoneal injection of streptozocin. Five wounds were created on the back of each rat, and treated as control (untreated), vasaline-treated, and 5%, 10% or 15% *Teucrium polium* extract-treated. The results showed that *Teucrium polium* extract stimulated wound healing by enhancing the rate of wound retraction, angiogenesis, fibroblast proliferation, collagen deposition, and maturation. Although there was a reduction in the level of granulation tissue thickness deposition within the wound. The rate of the epithelial regeneration was improved, and the thickness of the regenerated epithelium was reduced. Overall, there was a promising impact of the extract on the process of wound healing through improving different phases of the process.

© 2020 Production by the University of Garmian. This is an open access article under the LICENSE

<https://creativecommons.org/licenses/by-nc/4.0/>

Keywords: Wound healing, *Teucrium polium*, Diabetes, phytochemicals

1. Introduction

A wound is a disruption of tissue integrity that might be caused by physical, chemical, or pathogenic organisms (bacteria and viruses) [1]. Wound healing is a physiologic process, passes through three main overlapping phases, which include inflammatory, proliferative, and remodeling phases. Directly after injury, the platelets are aggregated at the site to prevent blood loss, which is associated with the release of some factors (TGF β and PDGF) that attract the inflammatory cells, such as neutrophils and monocytes. In turn, they start cleaning up the site and release some cytokines, like CTGF and VEGF, to regulate and control the process of healing [2, 3]. The recruited fibroblasts to the site start proliferation, and contribute in the building up the extracellular matrix and granulation tissue formation through inducing fibroplasia, angiogenesis and a loose matrix, which is mainly made of type I collagen, glycoprotein, fibronectin, and hyaluronic acid [3].

Re-epithelialization also occurs during proliferative phase; keratinocytes proliferate and migrate from the wound edges to the center of the wound to regenerate new epithelium [4, 5]. At the start of the remodeling phase, collagen bundles start to increase in their diameters and become more organized, thereby providing more tensile strength [4, 6]. Also, transformed fibroblasts to myofibroblasts enhance, and facilitate wound contraction [6, 7]. The excess extracellular matrix is subsequently removed, and the wound healing process is completed [2].

Diabetes mellitus is a metabolic disorder characterised by hyperglycaemia that predisposes sufferers to sever and chronic complications that might affect the eyes, blood vessels, kidneys, and the nerves [8]. It appears to have a deleterious consequences on the process of wound healing via interfering nearly all phases of wound healing [9]. During inflammatory phase [10, 11], the leukocytes infiltration and their phagocytic abilities seem to be impaired [10]. Also the vascular system might be disturbed at the site of injury that interferes with the delivery of oxygen and nutrients to the site. Subsequently, that might lead to a prolonged

* Corresponding author

E-mail address: sadat.aziz@univsul.edu.iq (Instructor).

Peer-reviewed under the responsibility of the University of Garmian.

inflammatory phase, and excessive granulation tissue formation [9]. These defects appear to be associated with the thickening of the capillaries' basement membrane and impaired angiogenesis [12].

Teucrium polium is a medicinal plant that has been used as a traditional medicine for more than 2,000 years and it belongs to the *Lamiaceae* family [13]. Locally, it is known as Bonxosha, which refers to its pleasant odor. It seems to have several medical advantages. Such as antipyretic, anti-fungal, anti-spasmodic, anti-rheumatic, carminative, antibacterial [14], anti-cancer [13] and hypoglycemic effects [15]. To the best of our knowledge, there are not any reported data about the effect of *Teucrium polium* extract in Kurdistan region on the process of wound healing, especially in diabetic rats. Meanwhile, *T. polium* is a local wild plant, and well-recognized for its medical effects. We hypothesized that *Teucrium polium* total phytochemical extract enhances the process of wound healing in diabetic rats. Therefore, the aims of the study was to investigate the effect of different concentrations of the plant extract on the process of wound healing. Meanwhile, there are increased demands on the natural and biological materials for treating wounds to avoid undesirable side effects of the chemically derived-agents [16].

2. Materials and Methods

2.1. Plant Collection

The plant has been identified confirmed, and authenticated by the Kurdistan Botanical Foundation (<http://kurdistanbotanical.org/>). The aerial parts of the *Teucrium polium* were collected on June 2018 around Sulaymaniyah province. The plant was washed thoroughly with distilled water to remove adhered dirt and dust, dried in the shade at room temperature, then ground into a fine powder using an electrical blender. The powder was kept properly in a sealed container, and stored at 4 °C.

2.2. Phytochemical extraction and ointment preparation

The *Teucrium polium* phytochemical extract was obtained by adding 12 ml of the solvent (70% methanol) (Emsure-Germany) to one gram of the powdered aerial-part of the plant. The mixture was incubated in a shaking incubator (LabTech-Korea) at 25 °C for 48-72 h, 200 rpm. Then the extract was filtered using filter paper. The flow-through was concentrated and dried using a vacuum rotatory evaporator (Heidolph-Germany) at 35-40 °C, and freeze drier (Christ LCG-Germany). To make ointments with different concentrations, we mixed three different concentration (5%, 10%, and 15%) of the extract with vaseline (weight/weight) (Rose Polymer-Germany). The prepared ointments kept in well-sealed dark containers, and stored in refrigerator at 4°C.

2.3. Experimental Animals

All studies were conducted according to the principles of the ethics after approval by the University of Sulaimani, College of Veterinary Medicine Ethics Committee (No-2, section-3, 19.01.2020). Rats were housed under standard conditions of temperature (25±2 °C), normal photo-periodicity of 12 hr dark/ light system, and a relative humidity of 45-55 %. They have been fed with a standard diet. All operations on animals were done under an aseptic technique.

2.4. Experimental Design

Twenty healthy adult albino rats, aged between 8 to 12 weeks, were used, each of which weighing 250–350 g. After induction of diabetes, five excisional wounds were created on the back of each rat, and individually caged. Each wound was treated once per day with its own treatment (100 mg) as control-untreated wounds, vaseline; vehicle-treated wounds, 5%, 10% or 15% extract-treated wounds. 3-4 rats were sacrificed at day-2 (N=3), day-7 (N=3), day-14 (N=3), and day-21 (N=4) after the creation of the wounds.

2.5. Induction of diabetes

Rats were fasted for 24 hours, then after diabetes was induced by a single intraperitoneal injection of freshly prepared streptozocin (55mg/kg b.w.) (sigma). The blood sugar was monitored using glucose meter (Rowenta-Germany). Rats with blood sugar levels of more than 11.11mmol/L were considered to have diabetes.

2.6. Creation of the Excision wound

The wounds were created under sterile conditions. The rats were anesthetized by injecting (0.5 ml/ kg/rat) of the anesthetic cocktail. The cocktail was prepared by mixing 1 ml of 50% ketamine (Fresenius Kabi-India) with 0.25 ml of 20% xylazine (Alfasan-Holland). After shaving, a cutting line on the back of each rat was drew, then five full-thickness, paravertebral circular skin-excisions, 1 cm in diameter, and about 2 cm apart, was created using toothed forceps, a surgical blade and pointed scissors.

2.7. Measuring the rate of the wound retraction

To monitor the degree of the wound retraction, every 3 days just after the creation of the wounds until the end of the experiment, a photo of each wound was taken using ordinary camera (Canon-Japan), then the photos were analyzed using Image-J software (<https://imagej.nih.gov/ij/download.html>), see [supplementary material \(figure 1\)](#).

2.8. Epithelial Confluency

It was evaluated by measuring the length of the regenerated epithelium and the entire gap of the wound in micrometer using image focus software (<https://imagej.nih.gov/ij/download.html>) after being calibrated. Then it was counted by dividing the length of the regenerated epidermis on the entire wound gap.

2.9. Histopathology

The rats were euthanized using volatile chloroform (Chem-Lab-Belgium) in a closed jar, and the entire wound areas were collected at day-2, day-7, day-14 and day-21 after creation of the wound and fixed in 10% neutral formaldehyde solution (formalin) (Senatozin-Iran) at least for 24 hr.

After tissue processing and staining with H&E stain, different parameters, including inflammatory cells, angiogenesis, and fibroblast cells were evaluated. In addition, epidermis thickness, granulation tissue and collagen deposition thickness were measured using image focus software after being calibrated for each parameter at day-2, day-7, day-14 and day-21. Collagen density was measured using IMAGE-J Software after being stained with Masson's Trichrome stain (Biognost-Croatia), see supplementary material (figure 2).

2.10. Statistical analysis

Statistical analysis was by one-way ANOVA. Data were distributed evenly around the mean value, as established using Levene's test for homogeneity of variant.

3. Results and Discussion

Wound healing, particularly in diabetic patients, has become a challenge throughout the world. Phytochemicals, which are natural products that produced by plant under certain circumstance, have drawn the attention of the researchers, and have been found to be critical in the process of wound healing. *Teucrium polium*, which is a local wild plant, seems to be rich in phytochemicals, including phenolic compounds (gallic acid, caffeic acid, *chlorogenic acid*), and flavonoids (catechin, rutin, luteolin, quercetin and apigenin) [17,18, 20]. The effect of different concentrations of hydroalcoholic extract of *Teucrium polium* on wound healing at different time points were evaluated through measuring the changes in the rate of wound retraction, the inflammatory cell infiltration, angiogenesis, fibroblast proliferation, the epidermal

thickness, epidermal regeneration, granulation tissue thickness, collagen deposition thickness and collagen density.

After measuring the wound retraction in square centimeter at different time points using image-J software. The results showed that the size of the extract-treated wounds (5%, 10% or 15%) were significantly ($P<0.05$) reduced, especially, at day 7, day-14, and day-17 of the treatment in comparison with control-untreated and vaseline treated wounds at the same time points. Higher concentrations of the extract (10% or 15%) were found to be more effective in comparison with 5% extract, particularly at day-7 and day-11 of the treatment (Figure-1A). The increase in the wound retraction rate seems to have positive effects on the process of wound healing by reducing the chance of infection and stabilizing the underlying tissue, and by attenuating the release of the inflammatory mediators [21, 22]. The wound surface retraction appears to be related to the stimulatory effect of the extract on the tissue matrix production, which is directly related to the fibroblast proliferation and collagen deposition [29].

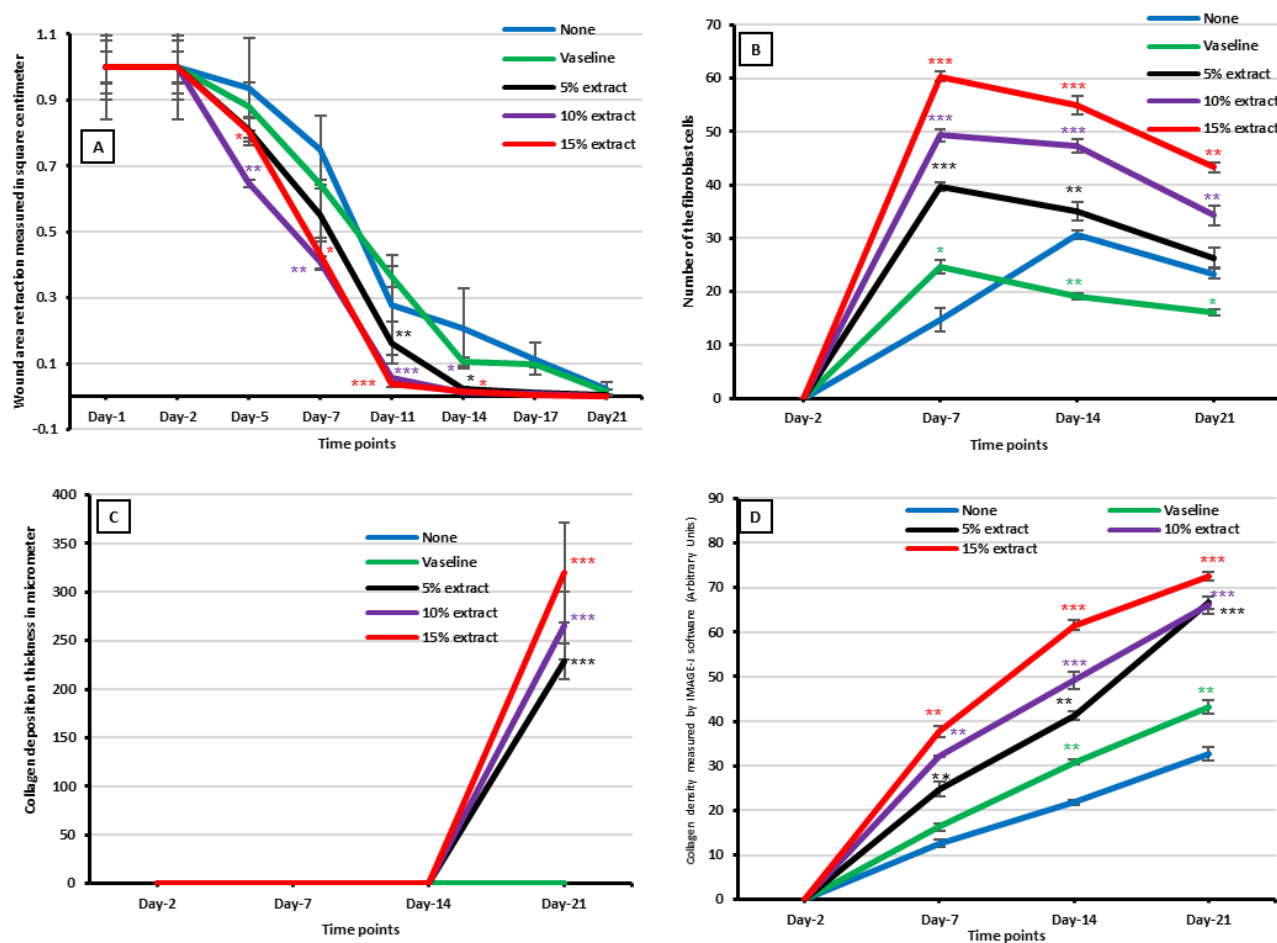


Figure 1: The effect of different concentrations of hydroalcoholic extract of *Teucrium polium* on wound area retraction (Panel-A), Fibroblast proliferation (Panel-B), collagen deposition thickness (Panel-C), collagen density (panel-D) in the excisional wounds of diabetic rats at different time points as indicated below each graph. None; untreated group, Vaseline; Vehicle, 5%, 10% and 15% extract; extract concentrations that suspended in vaseline. Values are means±standard errors for N=3-4.

The extract was found to induce a prominent ($P<0.001$) increase in the number of the fibroblasts in the extract-treated wounds compared to control-untreated and vaseline-treated wounds at day-7. Then after, there was a slight and steady declining in the numbers of fibroblasts at day-14, and day-21. But still, the number of fibroblasts were significantly ($P<0.005$) higher, particularly, in wounds which had been

treated with 10% and 15% extract compared to that of control-untreated and vaseline-treated wounds at day-14 and day-21. Overall, 15% extract was found to be more effective in inducing fibroblast proliferation compared to that of 5% and 10% extract throughout the course of the experiment (Figure-1B, and Figure-3). During wound healing the fibroblasts undergoes phenotypic changes under the

regulatory effects of some cytokines (TGF- β and PDGF), and differentiate to myofibroblasts. The aligned myofibroblast along the

borders of the extracellular matrix leads to generation of a constrictive force that induce, and facilitate wound closure [23].

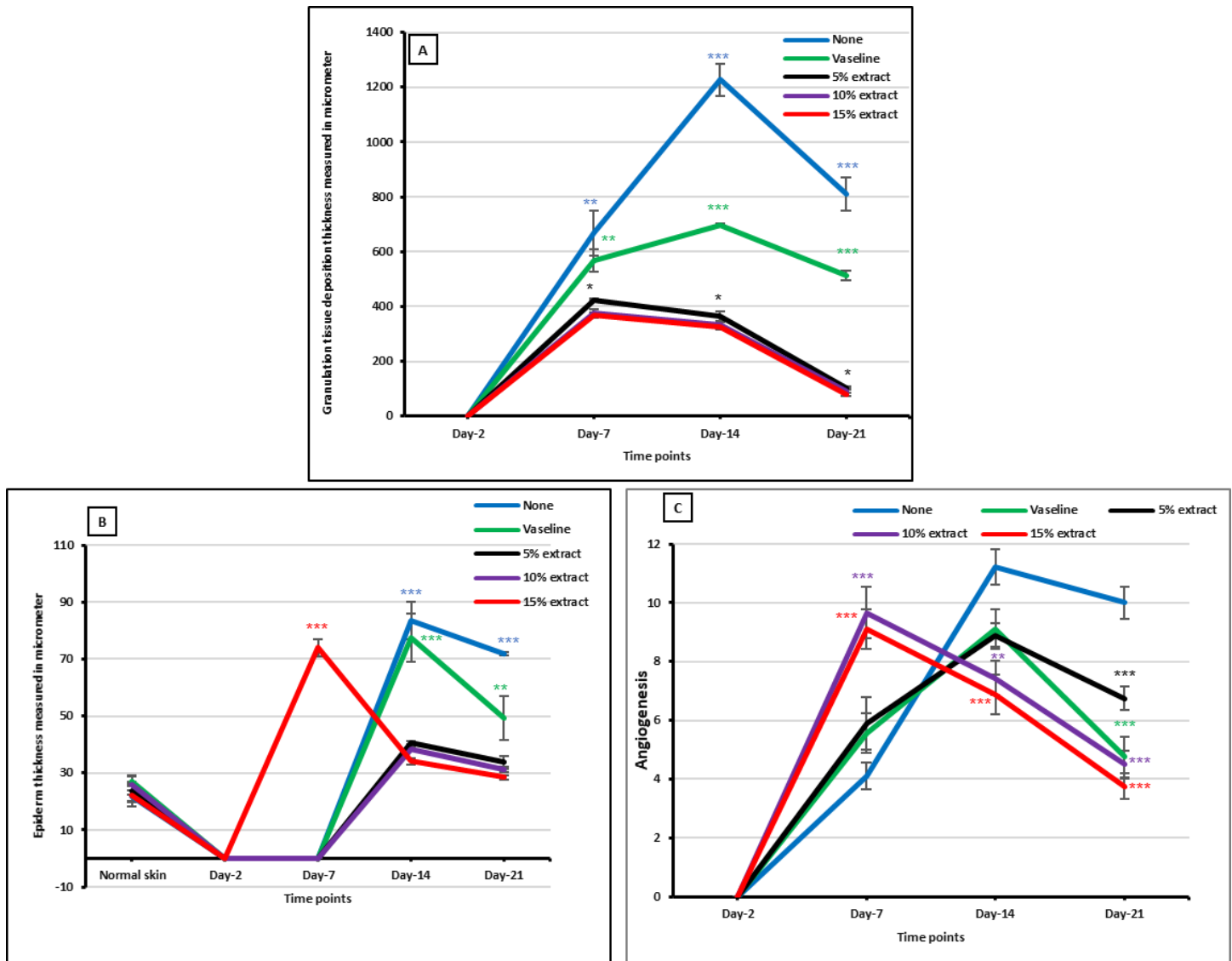


Figure 2: The effect of different concentrations of hydroalcoholic extract of *Teucrium polium* on granulation tissue deposition, (Panel-A), epidermis thickness (Panel-B), and angiogenesis (Panel-C), in the excisional wounds of diabetic rats at different time poin as indicated below each graph. None; untreated group, Vaseline; Vehicle, 5%, 10% and 15% extract; extract concentrations that suspended in vaseline. Values are means \pm standard errors for N=3-4.

The collagen deposition thickness was measured in micrometer using image focus software after being stained with H&E stain. The result showed that only the extract-treated (5%, 10% or 15%) wounds had a remarkable ($p < 0.001$) accumulation of collagen, especially after day-14, and peaked at day-21 compared to that of vaseline and control-untreated wounds (Figure-1B, and Figure-3). While the collagen density, which has been measured in micrometer using image-j software, were found to be higher ($P < 0.005$) in the extract-treated wounds (5%, 10% or 15%) at day-7, day-14 and day-21 in comparison to that of control-untreated and vaseline-treated wounds (Figure-1D, and Figure-4). The collagen fiber were thinner, with the fascicular arrangement, and horizontal orientation in the control-untreated and vaseline-treated wounds. While in the extract-treated wounds, the collagen fibers were thicker with a reticular arrangement, and had vertical or multidirectional orientation (Figure-4). A reduction in the number of fibroblasts, and a concomitant increase in the collagen

consistency and collagen bundle thickness, which were observed in the extract treated wounds, particularly at day-21, might be associated with the maturation of collagen fibers, which is neither fibroblast nor collagen fiber number-dependent process. The conversion of thread-like collagen fibers to thicker and organized bundles providing more tensile strength, enhance the rate of healing [4], accelerate tissue regeneration and enhance skin firmness [24, 25]. However, any disturbance in the deposition and maturation of the collagen fibers may reduce wound strength, and cause wound dehiscence [26]. Similar to that of our finding, crude extract of *Acanthus polystachyus Delile* was found to enhance the rate of wound retraction of excisional and incisional wounds in normal Swiss albino mice [27]. Another study who used *Copaifera pauper* extract in diabetic Swiss *Webster* mice, revealed a better wound closure, and higher level of collagen deposition compared to that of collagenase treated wounds [28]. In addition, other phytochemical molecules, such as morin, rutin, and chrysin were also

reported to enhance the function of fibroblasts by inducing the synthesis, and secretion of collagen^[29].

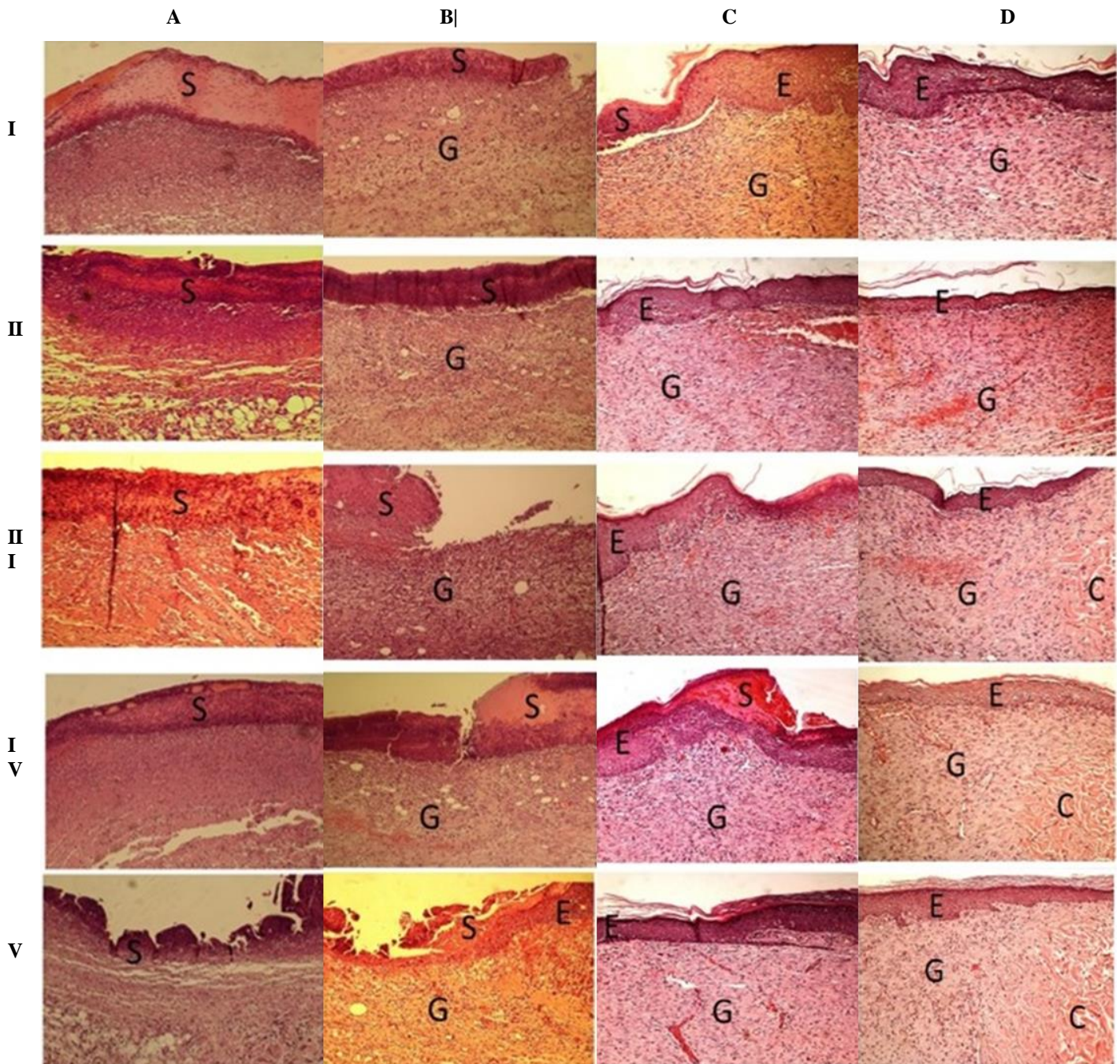


Figure 3: The effect of different concentrations of hydroalcoholic extract of *Teucrium polium* on the wound healing process in the excisional wounds of diabetic rats at different time points. The sections were taken at day-2 (panel-A), day-7 (panel-B), day-14 (panel-C) and day-21 (panel-D), after the creation of the wounds, stained with H&E stain. **I;** control-untreated wound, **II;** Vaseline treated wound, **III;** 5% extract-treated wound, **IV;** 10% extract-treated wound, and **V;** 15% extract-treated wound. Collagen (C), Epidermis (E), Granulation tissue (G), Scab (S). (100 X).

Epithelium, which can act as a physical barrier, is a critical structure of the skin and its regeneration has fundamental impacts on the process of wound healing^[30]. Under hyperglycaemic conditions, keratinocytes have been found to have a slower migration and proliferation capacities in both human and murine models^[31, 32]. Apoptosis, which usually occurs concurrently with reepithelialization, was reported to be disturbed in diabetic and induces retarded wound closure^[33]. However,

the result of the study revealed that only 15% extract-treated wounds was found to be successful in inducing epithelial regeneration (19% confluence) at day-7 in comparison with the other treatments. At day-14, the epithelium of all wounds, which had been treated with different concentrations of the extract, were found to be 100% confluence compared with control-untreated (37% confluence) and vaseline-treated (51% confluence) wounds. While the control-untreated (47%

confluence) and vaseline-treated (73% confluence) wounds were failed to be completely regenerated even at the end of the experiment (Table-1).

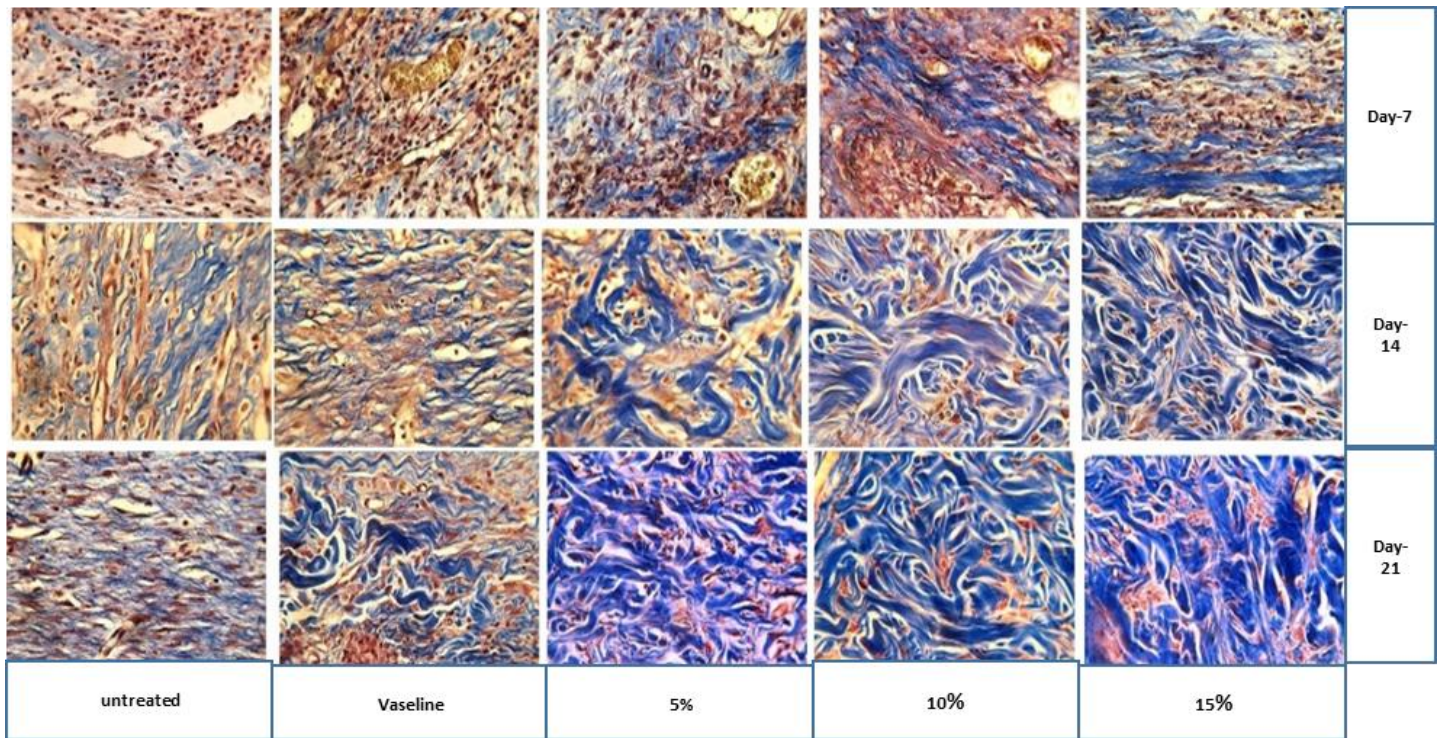


Figure 4: The effect of different concentrations of hydroalcoholic extract of *Teucrium polium* on collagen density in the excisional wounds of diabetic rats at different time points as indicated on the right side of the section. Stained with Masson's Trichrome stain. Collagen fibers stained in blue (400X).

Table 1: The effect of different concentrations of hydroalcoholic extract of *Teucrium polium* on the wound reepithelialization confluency in diabetic rats at different time points.

Time	Epithelial confluence			
	Day-2	Day-7	Day-14	Day-21
None	0%	0%	37%	47%
Vaseline	0%	0%	51%	73%
5% extract	0%	0%	100%	100%
10% extract	0%	0%	100%	100%
15% extract	0%	19%	100%	100%

*None; Control-untreated, Vaseline; Vehicle, 5%, 10% or 15% extract; extract concentrations that was suspended in vaseline. The length of the regenerated epithelium and the entire gap of the wound were measured using image focus software after being cali

Epidermal thickness was measured in micrometer using image focus software after being calibrated. The results showed that epidermis was only regenerated in the wounds, which had been treated with 15% extract at day-7. While, there was a drastic ($P < 0.01$) increase in the epidermal thickness of the control-untreated and vaseline-treated wounds compared to that of the extract-treated wounds at day-14 and day-21. Overall, the formed epithelium in the extract-treated wounds were thinner and regular compared with vaseline-treated and control-untreated wounds, which had thicker and irregular epithelium (Figure-2B, Figure-3). Gallic acid and apigenin, which have been detected in *Teucrium polium* extract, seem to accelerate the migration of the keratinocytes and fibroblasts in hyperglycemic conditions and most

likely to activate the wound healing related growth factors [34-36]. Activated TGF- β seems to trigger the epithelial-mesenchymal transition, controls fibroblast proliferation, and increases collagen deposition, which is followed by keratinocyte-mesenchymal differentiation and induction of re-epithelialization [37, 38]. Dewangan, Bais [39] reported a higher regeneration rate with a thinner epidermis in wounds that had been treated with different concentrations of the *Solanum xanthocarpum Schrad* and *Wendl* extract. The excisional and incisional wounds, which had been treated with crude extract of *Acanthus polystachyus Delile* were found to have a faster reepithelialization rate compare to untreated-wounds in Swiss albino mice [27]. Consistence with our finding, *Copaifera pauper* extract were reported to improve reepithelialization processes in diabetic Swiss *Webster* mice compared to that of collagenase treated wounds [28].

The process of angiogenesis was evaluated by counting the number of the regenerated blood vessels under 40X objective lens. The result showed that the number of the regenerated blood vessels was significantly ($P < 0.05$) higher in the extract-treated (5%, 10%, or 15%) wounds at day-7 compared to that of the control-untreated wounds. However, on day-14, the number of the newly formed blood vessels were declined in the 10% or 15% extract-treated wounds in comparison to that of the untreated wounds, vaseline-treated and 5% extract-treated wounds. On day-21 of the treatment, there was a pronounced reduction ($P < 0.001$) in the number of the blood vessels in the extract-treated wounds compared to control-untreated wounds (Figure-2C).

The observed pattern of the increase in the number of the regenerated blood vessels at the early days of the treatment, which was followed by a declined angiogenesis, indicate a promising effect of the extract on the

process of wound healing. This effect was more likely to be related to some specific phytochemicals. Such as chlorogenic acid, which

Table 2: Effect of *Teucrium polium* hydroalcoholic extract on the number of inflammatory cell infiltration (Neutrophils, macrophage, lymphocytes, eosinophils and mast cells) in excisional wounds of diabetic rats.

Time Points Treatments	Day 2	Day 7	Day 14	Day 21
Neutrophils				
none	^A 14.0±0.57	^A 30.66±0.88	^A 0.00±0.00	^A 0.00±0.00
Vehicle	^{AB} 13.0±0.57	^B 5.000±0.57	^A 0.00±0.00	^A 0.00±0.00
5% extract	^B 11.3±0.88	^C 0.00±0.00	^A 0.00±0.00	^A 0.00±0.00
10% extract	^C 8.0±0.57	^C 0.00±0.00	^A 0.00±0.00	^A 0.00±0.00
15% extract	^D 2.0±0.57	^C 0.00±0.00	^A 0.00±0.00	^A 0.00±0.00
Macrophages				
none	^A 19.0±0.57	^A 33.0±3.21	^A 24.0±0.57	^A 12.30±0.88
Vehicle	^A 20.3±0.88	^B 25.0±1.73	^A 22.3±0.88	^A 10.30±0.88
5% extract	^B 13.3±0.88	^C 12.0±1.15	^B 10.3±0.88	^B 7.60±0.33
10% extract	^C 9.33±0.33	^{CD} 7.0±0.57	^C 5.30±0.88	^C 3.33±0.88
15% extract	^C 8.00±0.57	^D 5.3±0.88	^C 3.30±0.33	^C 1.66±0.33
Lymphocytes				
none	^A 4.0±0.57	^A 12.0±0.57	^A 3.0±0.00	^A 2.3±0.33
Vehicle	^B 6.0±0.57	^A 12.3±1.20	^A 4.0±0.57	^A 2.3±0.33
5% extract	^{AB} 5.0±0.57	^A 12.3±1.45	^B 10.3±0.88	^A 2.0±0.00
10% extract	^A 4.0±0.57	^B 19.6±0.88	^C 8.0±0.57	^B 1.0±0.00
15% extract	^A 3.6±0.33	^C 24.6±1.45	^C 6.6±0.88	^C 0.0±0.00
Eosinophils				
None	^A 0.00±0.00	^A 0.00±0.00	^A 0.00±0.00	^A 0.00±0.00
Vehicle	^A 0.00±0.00	^A 0.00±0.00	^A 0.00±0.00	^A 0.00±0.00
5% extract	^A 0.00±0.00	^A 0.00±0.00	^A 0.00±0.00	^A 0.00±0.00
10% extract	^A 0.00±0.00	^A 0.00±0.00	^A 0.00±0.00	^A 0.00±0.00
15% extract	^A 0.00±0.00	^A 0.00±0.00	^A 0.00±0.00	^A 0.00±0.00
Mast cells				
None	^A 0.00±0.00	^A 0.00±0.00	^A 0.00±0.00	^A 0.00±0.00
Vehicle	^A 0.00±0.00	^A 0.00±0.00	^A 0.00±0.00	^A 0.00±0.00
5% extract	^A 0.00±0.00	^{AB} 0.33±0.33	^B 0.00±0.00	^A 0.00±0.00
10% extract	^A 0.00±0.00	^{AB} 0.66±0.33	^{BC} 1.33±0.33	^A 0.00±0.00
15% extract	^A 0.00±0.00	^B 1.00±0.00	^C 2.00±0.57	^A 0.00±0.00

*Superscripts on the left of the means indicate statistical differences between the groups.

* Values are means±standard error. Values are means±standard errors for N=3-4. Statistical analysis was by one way ANOVA. *P<0.05. Data were distributed evenly around the mean value, as established using Levene's test for homogeneity of variant.

already had been detected in *Teucrium polium* extracts. Those phytochemicals were found to enhance the capillary-like tube formation of endothelial cells and angiogenesis [19]. In addition, other medicinal plants, including *Aloe barbadensis*, *Panax notoginseng*, and *Astragalus membranaceus* extracts have been reported to enhance healing process via inducing angiogenesis that could be through up-regulation of VEGF, VEGFR, TGFβ1, and activation of ERα and ERβ and MAPK signaling [41]. Although picroliv, a phytochemical extracted from the roots of *Picrorhiza kurroa*, was reported to induce angiogenesis, which might be enhanced through the expression of vascular endothelial growth factor (VEGF) [42]. Different nanostructure

of plant extracts and their phytochemicals were found to modulate the process of wound healing by stimulating the process of angiogenesis through upregulation of fibroblast growth factor (FGF) and VEGF [43]. In parallel to that of fibroplasia, angiogenesis is a crucial step for achieving a successful healing, and reduce the chance of an abnormal scar formation [40].

The granulation tissue thickness, which was measured in micrometer, using image-focus software was found to be thinner (P<0.05) in the extract-treated (5%, 10%, or 15%) wounds at day-7, day-14 and day-21 compared to that of control-untreated and vaseline-treated wounds

(Figure-2A, Figure-3), that indicates an improvement in the process of wound healing^[44]. Because hypergranulation is problematic for wound healing and it is more likely to be associated with fibroplasia, and prolonged angiogenesis and inflammation^[43, 45, 46] which might impair the process of wound healing through interfering epithelial cells migration across the surface of the wound bed^[47], and disturbing granulation tissue remodeling, which is critical for restoring damaged tissue architecture^[44]. Post-injury inflammatory response control is known to be critical in wound healing^[43, 48] by reducing a chance of microbial infection, cellular debris degradation, releasing growth factors and cytokines. However, a prolonged inflammatory phase during wound healing might lead to a delay in the healing process^[20, 43].

The inflammatory cells (neutrophils, macrophages, lymphocytes, eosinophils, mast cells) were counted at different time points by divided each slide into 12 equal squares after being photographed under power 400X. The results showed that the number of neutrophils, particularly in the wounds, which had been treated with 10% or 15% extract, were significantly ($P \leq 0.01$) lower compared to control-untreated and vaseline-treated wounds on day-2. While on day-7, neutrophils totally disappeared in the extract-treated (5%, 10% or 15%) wounds. However, there was a sharp increase in the number of neutrophils in the control-untreated wounds. In addition, there was a significant ($P < 0.05$) difference between control-untreated and vaseline-treated wounds (Table-2). Neutrophils enhance wound healing through express cytokines (TNF α and VEGF) that stimulate reepithelialization and angiogenesis^[49, 48]. Neutrophils should be cleared at the wound site^[50], at the early stages of the inflammatory phase. Otherwise, they exert deleterious effects by inhibiting wound healing^[51].

The numbers of macrophages were significantly ($P \leq 0.05$) lower in the extract-treated wounds (5%, 10%, or 15%) compared to the control-untreated and vaseline-treated wounds throughout the course of the treatment. Meanwhile, 10% and 15% extract-treated wounds revealed significantly ($P \leq 0.05$) higher number of lymphocytes in comparison to 5% extract-treated wounds, control-untreated and vaseline-treated wounds. Then the number of lymphocytes started to decline on day-14 and day-21 of the experiment (Table-2). The controlling activities of macrophages are important in providing a local inflammatory response that might be adequate to initiate repair and to prevent fibrotic activity^[52].

An increase in the number of the lymphocytes in the early days of the treatment, then tending to disappear at the end of the experiment (Table-2) might be related to an improvement in the process of wound healing as the process of wound healing appears to be enhanced by lymphocytes^[53].

A significant ($P \leq 0.05$) increase in the number of the mast cells were only observed in the wounds, which had been treated with the extract at day-7 and day-14, especially, in the wounds, which had been treated with 15% extract (Table-2). A marginal increase in the number of mast cells in the extract-treated wounds might have a role in regulating the inflammatory phase. Mast cells granules contain a wide spectrum of vasoactive and pro-inflammatory mediators, including preformed molecules such as histamine, serotonin, TNF, kinins, and proteases, that might induce wound healing through regulating acute inflammatory responses^[54].

4. Conclusion

In conclusion, hydroalcoholic extract of *Teucrium polium* found to have critical effects on the process of wound healing in diabetic rats by stimulating the process of wound healing through enhancing fibroblasts proliferation, collagen deposition and maturation, epithelial confluency, angiogenesis, and inflammatory cells infiltration with a minimum scar formation.

Conflict of Interest

None.

Authors contribution

Salih, M.A. has done all the lab work, who supervised by Abdullah, A. N. and Aziz S. A.

Supplementary Information

Supplementary information related to this article can be found at: ([Supplementary](#)) Salih et al. *Passer 1* (2020) 37- 45

References

1. Werner S, Grose R. Regulation of wound healing by growth factors and cytokines. *Physiological reviews*. Jul;83(3):835-70. (2003).
2. Broughton, G.n., J.E. Janis, and C.E. Attinger, Wound healing: an overview. *Plast Reconstr Surg*. **117**(7 Suppl). (2006).
3. Robson, M.C., D.L. Steed, and M.G. Franz, Wound healing: biologic features and approaches to maximize healing trajectories. *Current problems in surgery*. **38**(2): p. 72-140. (2001)
4. Baum, C.L. and C.J. Arpey, Normal cutaneous wound healing: clinical correlation with cellular and molecular events. *Dermatologic surgery*. **31**(6): p. 674-686. (2005).
5. Hunt, T.K., H. Hopf, and Z. Hussain, Physiology of wound healing. *Advances in skin & wound care*. **13**: p. 6. (2000).
6. Clark, R.A., Regulation of fibroplasia in cutaneous wound repair. *The American journal of the medical sciences*. **306**(1): p. 42-48. (1993).
7. Li, B. and J.H.-C. Wang, Fibroblasts and myofibroblasts in wound healing: force generation and measurement. *Journal of tissue viability*. **20**(4): p. 108-120. (2011).
8. Ahmed, N., Advanced glycation endproducts—role in pathology of diabetic complications. *Diabetes research and clinical practice*. **67**(1): p. 3-21. (2005).
9. Sharp, A. and J. Clark, Diabetes and its effects on wound healing. *Nursing Standard* (through 2013). **25**(45): p. 41. (2011).
10. Lioupis, C., Effects of diabetes mellitus on wound healing: an update. *Journal of wound care*. **14**(2): p. 84-86. (2005).
11. Kidman, K., Tissue repair and regeneration: the effects of diabetes on wound healing. *The Diabetic Foot*. **11**(2): p. 73-73. (2008).
12. Falanga, V., Wound healing and its impairment in the diabetic foot. *The Lancet*. **366**(9498): p. 1736-1743. (2005).
13. Khazaei, M., et al., Review on *Teucrium polium* biological activities and medical characteristics against different pathologic situations. *Journal of Contemporary Medical Sciences*. **4**(1). (2018).
14. Said, O., et al., Ethnopharmacological survey of medicinal herbs in Israel, the Golan Heights and the West Bank region. *Journal of ethnopharmacology*. **83**(3): p. 251-265. (2002).
15. Gharaibeh, M.N., H.H. Elayan, and A.S. Salhab, Hypoglycemic effects of *Teucrium polium*. *Journal of ethnopharmacology*. **24**(1): p. 93-99. (1988)
16. Lewis, W.H. and M.P. Elvin-Lewis, Medicinal plants as sources of new therapeutics. *Annals of the Missouri Botanical Garden*. p. 16-24. (1995).
17. Djordjvec, O.M., et al., Polyphenolic contents of *Teucrium polium* L. and *Teucrium scordium* L. associated with their protective effects against MMC-induced chromosomal damage in cultured human peripheral blood lymphocytes. *Turkish Journal of Biology*. **42**(2): p. 152-162. (2018).

18. Tsuruya, M., et al., Acceleration of proliferative response of mouse fibroblasts by short-time pretreatment with polyphenols. *Applied biochemistry and biotechnology*. **174**(6): p. 2223-2235. (2014).
19. Moghadam, S., et al., Wound healing potential of chlorogenic acid and Myricetin-3-O- β -Rhamnoside isolated from *Parrotia persica*. *Molecules*. **22**(9): p. 1501. (2017).
20. Süntar, İ., et al., Investigating wound healing, tyrosinase inhibitory and antioxidant activities of the ethanol extracts of *Salvia cryptantha* and *Salvia cyanescens* using in vivo and in vitro experimental models. *Journal of ethnopharmacology*. **135**(1): p. 71-77. (2011).
21. Pastar, I., et al., Epithelialization in wound healing: a comprehensive review. *Advances in wound care*. **3**(7): p. 445-464. (2014)
22. Li, J., J. Chen, and R. Kirsner, Pathophysiology of acute wound healing. *Clinics in dermatology*. **25**(1): p. 9-18. (2007).
23. Barrientos, S., et al., Growth factors and cytokines in wound healing. *Wound repair and regeneration*. **16**(5): p. 585-601. (2008).
24. Duman, N., et al., Topical folic acid enhances wound healing in rat model. *Advances in medical sciences*. **63**(2): p. 347-352. (2018).
25. Kim, J. and C.-M. Lee, Wound healing potential of a polyvinyl alcohol-blended pectin hydrogel containing *Hippophae rhamnoides* L. extract in a rat model. *International journal of biological macromolecules*. **99**: p. 586-593. (2017).
26. Manzuoehr, R., et al., Effectiveness of topical administration of anethum graveolens essential oil on MRSA-infected wounds. *Biomedicine & Pharmacotherapy*. **109**: p. 1650-1658. (2019).
27. Demilew, W., G.M. Adinew, and S. Asrade, Evaluation of the Wound Healing Activity of the Crude Extract of Leaves of *Acanthus polystachyus* Delile (Acanthaceae). *Evidence-Based Complementary and Alternative Medicine*. **2018**: p. 9. (2018).
28. Amorim, J.L., et al., Wound healing properties of *Copaifera paupera* in diabetic mice. *PLOS ONE*. **12**(10): p. e0187380. (2017).
29. Stipcevic, T., J. Piljac, and D.V. Berghe, Effect of Different Flavonoids on Collagen Synthesis in Human Fibroblasts. *Plant Foods for Human Nutrition*. **61**(1): p. 27-32. (2006).
30. Thangavel, P., et al., Accelerated healing of diabetic wounds treated with L-glutamic acid loaded hydrogels through enhanced collagen deposition and angiogenesis: an in vivo study. *Scientific reports*. **7**(1): p. 10701. (2017).
31. Hehenberger, K., et al., Fibroblasts derived from human chronic diabetic wounds have a decreased proliferation rate, which is recovered by the addition of heparin. *Journal of dermatological science*. **16**(2): p. 144-151. (1998).
32. Blakytyn, R. and E. Jude, The molecular biology of chronic wounds and delayed healing in diabetes. *Diabetic Medicine*. **23**(6): p. 594-608. (2006).
33. Arana, V., et al., Healing of diabetic foot ulcers in L-arginine-treated patients. *Biomedicine & pharmacotherapy*. **58**(10): p. 588-597. (2004).
34. Rawat, S., et al., Wound healing agents from medicinal plants: a review. *Asian Pacific Journal of Tropical Biomedicine*. **2**(3): p. S1910-S1917. (2012).
35. S, R.J.R., M. Nadar, and M.S. Paulraj, Plant-Derived Compounds for Wound Healing-A Review. *Organic & Medicinal Chemistry International Journal*. **5**: p. 001-005. (2018).
36. Lopez-Jomet, P., et al., Effects of potassium apigenin and verbena extract on the wound healing process of SKH-1 mouse skin. *International wound journal*. **11**(5): p. 489-495. (2014).
37. Cañedo-Dorantes, L. and M. Cañedo-Ayala, Skin Acute Wound Healing: A Comprehensive Review. *International Journal of Inflammation*. **2019**. (2019).
38. desJardins-Park, H.E., D.S. Foster, and M.T. Longaker, Fibroblasts and wound healing: an update. *Regenerative Medicine*. **13**(5): p. 491-495. (2018).
39. Dewangan, H., et al., Potential wound healing activity of the ethanolic extract of *Solanum xanthocarpum* schrad and wendl leaves. *Pakistan journal of pharmaceutical sciences*. **25**(1). (2012).
40. Greaves, N.S., et al., Current understanding of molecular and cellular mechanisms in fibroplasia and angiogenesis during acute wound healing. *Journal of Dermatological Science*. **72**(3): p. 206-217. (2013).
41. Majewska, I. and E. Gendaszewska-Darmach, Proangiogenic activity of plant extracts in accelerating wound healing-a new face of old phytomedicines. *Acta biochimica polonica*. **58**(4). (2011).
42. Singh, A.K., et al., Picroliv, a Phytochemical Enhances Wound Healing in Rats. *Wound Repair and Regeneration*. **13**(2): p. A4-A27. (2005).
43. Hajialyani, M., et al., Natural product-based nanomedicines for wound healing purposes: therapeutic targets and drug delivery systems. *International Journal of Nanomedicine*. **13**: p. 5023-5043. (2018).
44. Schulz, J.-N., et al., Reduced granulation tissue and wound strength in the absence of $\alpha 1 \beta 1$ integrin. *Journal of Investigative Dermatology*. **135**(5): p. 1435-1444. (2015).
45. Widgerow, A. and K. Leak, Hypergranulation tissue: evolution, control and potential elimination. *Wound Healing Southern Africa*. **3**(2): p. 1-3. (2010).
46. Shalom, A. and L. Wong, Treatment of Hypertrophic Granulation Tissue with Topical Steroids: 141. *Journal of Burn Care & Research*. **24**: p. S113. (2003).
47. Stevens, N.M., et al., Treatment in an outpatient setting for a patient with an infected, surgical wound with hypergranulation tissue. *The international journal of lower extremity wounds*. **8**(1): p. 37-44. (2009).
48. Kovtun, A., et al., Neutrophils in tissue trauma of the skin, bone, and lung: two sides of the same coin. *Journal of immunology research*. **2018**. (2018).
49. Makino, K., et al., Knockout of endothelial cell-derived endothelin-1 attenuates skin fibrosis but accelerates cutaneous wound healing. *PLoS One*. **9**(5): p. e97972. (2014).
50. de Oliveira, S., E.E. Rosowski, and A. Huttenlocher, Neutrophil migration in infection and wound repair: going forward in reverse. *Nature Reviews Immunology*. **16**(6): p. 378. (2016).
51. Landén, N.X., D. Li, and M. Stähle, Transition from inflammation to proliferation: a critical step during wound healing. *Cellular and Molecular Life Sciences*. **73**(20): p. 3861-3885. (2016).
52. Mescher, A.L., A.W. Neff, and M.W. King, Inflammation and immunity in organ regeneration. *Developmental & Comparative Immunology*. **66**: p. 98-110. (2017).
53. Swift, M.E., et al., Age-related alterations in the inflammatory response to dermal injury. *Journal of Investigative Dermatology*. **117**(5): p. 1027-1035. (2001).
54. Komi, D.E.A., K. Khomtchouk, and P.L. Santa Maria, A Review of the Contribution of Mast Cells in Wound Healing: Involved Molecular and Cellular Mechanisms. *Clinical reviews in allergy & immunology*. p. 1-15. (2019).